

Live-surgery

Sulcoflex (Rayner), Additive IOL

M. Amon

Akademisches Lehrkrankenhaus Barmherzige Brüder Wien
Consultant: Zeiss, Morcher, Rayner

M. Amon; DGII 09

Patientendaten

- 53a/weiblich
- OP: 2007; Phako+HKL+LRI
- primäre IOL: Tecnis multifokal (Silikon) +30dpt
- Refraktion prä Sulcoflex: +1,75dpt / -0,5cyl
- VK: 4,1mm

M. Amon; DGII 09

Chirurgie

- Berechnung:
R-vergence formula, Haigis Berechnungsprogramm
IOL-master (pseudophake IOL)
-7/+7dpt:
Refraktion mal 1,5 (hyperop), bzw. mal 1,2 (myop)
- 2.75mm CCI
- OVD
- Injektor
- Positionierung der IOL
- I/A
- „hydration“
- Antibiotikum

M. Amon; DGII 09


Rationale for IOL

Material:
hydrophilic acrylic: uveal biocomp.

Optic:
diameter (6.5): quality of vision, no optic-capture
round edge: reduction of dysphotopsia
concave posterior surface: no distortion of IOL-optics
IOL-neutral aspheric, multifocal (refractive), toric, toric/multifocal


Haptic:
„undulated“, diameter (13.5): centration, rotational stability
angulation (10°): uveal clearance, pigment dispersion/o. capt.
soft haptic with round edge: less tissue-reaction

M. Amon; DGII 09



Indications for the Sulcoflex IOL:

early/late secondary implantation:
ametropia, aniseikonia
primary:
high myopia
high hyperopia



M. Amon; DGII 09

Indications for the Sulcoflex IOL:

near and far vision (multifocal, monovision)



M. Amon; DGII 09

Indications
 astigmatism (toric, toric/multif.)

Additional indications:
 primary, early/late secondary implantation

"dynamic refraction":
 pediatric cataract (correct refractive change)
 silicone oil (correct refractive change)
 keratoconus (correct refractive change)
 dysphotopsia
 higher order aberrations (customised)
 "test-implant" (emmetropia/myopia or monovision; easy to remove)
 reduction of IOL stock (toric IOL stock)
 light filter
 drug delivery
 prismatic IOL
 phakic IOL
 aphakia

M. Amon; DGII 09

Conclusion

- surgery: safe and easy; less trauma than IOL-exchange; iridotomy?
- postop. refraction: stable with good predictability
- rotational stability: high (toric IOL)
- follow-up: without any severe complication (2 years); no block
- reversible procedure

Supplementary IOLs represent a promising, new concept for the various indications

M. Amon; DGII 09

Results

- IOP (range): 11 – 22mmHg; 1 eye elevation on day one
- LFCM: 5 - 30 photon counts/ms < than after phaco
- fibrin: 0
- iristrauma: 0

M. Amon; DGII 09

Results

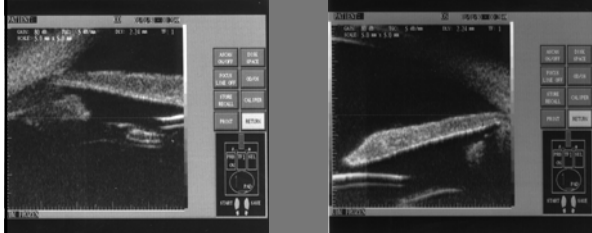

- pigmentdispersion: 0
- interlenticular opacification: 0
- LEC-ongrowth: 1

Results

- rotation: 0
- tilt: 0
- decentration: < 0.5mm from axis (sulcus/bag position)

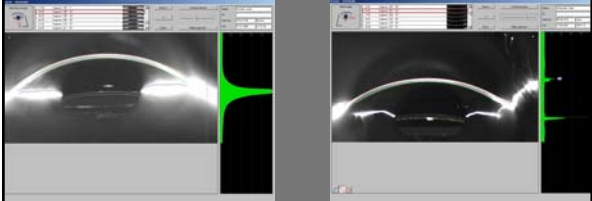

Results

- sulcus position: 100%
- positive iris-distance: 100%



Results

- positive optic-distance: 100%
- optic capture: 0



Results

- VA (mean) sc: 0.9
- refraction (range): +/- 0.25dpt from aim
- independency from glasses in those cases with multifocal Sulcoflex or multifocal primary IOL

